

UT Southwestern Department of Radiology

Ultrasound –Thyroid Gland Evaluation

PURPOSE:

To evaluate for diffuse or focal thyroid abnormalities and associated cervical lymph nodes*.

SCOPE:

Applies to all US Abdomen Complete studies performed in Imaging Services / Radiology

INDICATIONS:

- Signs (examples: thyromegaly, palpable nodule) or symptoms of hyper/hypothyroidism, dysphagia, neck pain, etc.
- Abnormal laboratory values
- Abnormal thyroid findings on other imaging studies
- Evaluate for thyroid malignancy in the setting of appropriate risk factors
- Follow up known thyroid abnormalities

CONTRAINDICATIONS:

- No absolute contraindications

EQUIPMENT:

Linear array transducer with a frequency range of 9-18 MHz or greater that allows for appropriate penetration and resolution depending on patient's body habitus

PATIENT PREPARATION:

- None

EXAMINATION:

GENERAL GUIDELINES:

A complete examination includes evaluation of both thyroid lobes and isthmus, as well as associated cervical lymph node regions, if indicated*.

EXAM INITIATION:

- Review any prior imaging, making note of prior thyroid nodules, lymph nodes, or other findings requiring comparison.
- Introduce yourself to the patient and explain test
- Verify patient identity using patient name and DOB
- Obtain patient history including symptoms. Enter and store data page.
- Place patient in supine position with the neck extended. A pillow/towel under the shoulders may facilitate maximum neck extension.

TECHNICAL CONSIDERATIONS:

- Review any prior imaging, making note of abnormalities or other findings requiring further evaluation.

* - For solid/predominantly solid nodules ≥ 1 cm, include lymph node survey. See US Neck Node Survey protocol for details

- Size of each thyroid lobe should be documented in 3 dimensions (longitudinal, obtained in sagittal plane, AP and transverse, obtained in transverse plane). Use compound measurement (split image), panoramic view, or wide field-of-view as needed. Thickness (AP) of the isthmus should be measured on the transverse view.
- Nodules should be documented without and with size measurements in 3 orthogonal dimensions and without and with color Doppler, preferably on using 2-on-1 imaging.
- For multinodular glands, each nodule should be evaluated independently for suspicious features. However, provide measurements for up to three largest (> 1cm) or most suspicious nodules per lobe, and up to two in the isthmus (see Appendix).
- Evaluate and number nodules from upper pole to lower pole, from right lobe to left:
 - *Nodule R1, Nodule R2, Nodule R3; Nodule L1, Nodule L2, Nodule L3; Nodule I1, Nodule I2.*
- * If solid or predominantly solid nodules ≥ 1 cm, survey the central compartment and lateral compartments to evaluate for abnormal or enlarged lymph nodes. See "US Neck Lymph Node Survey" protocol for more information.
 - * Anterior cervical levels are divided into central (Levels I and VI) and lateral (Levels II-IV) compartments. Posterior cervical lymph nodes are found in levels VA and VB.
 - **Normal lymph nodes should NOT be measured.** Suspicious lymph node features include rounded shape, loss of the central fatty hilum, irregular or lobulated cortex, heterogeneity, echogenic foci/calcifications, and cystic spaces. Size is a less useful marker. Short axis >1 cm is considered enlarged, however, Level II lymph nodes are commonly larger and still normal.
- Document tracheal deviation if present.

DOCUMENTATION:

- Thyroid Gland
 - Measurements:
 - Each lobe
 - Longitudinal view, longitudinal measurement
 - Transverse view, transverse and AP measurements at mid lobe
 - Isthmus, AP measurement
 - Grayscale images:
 - Midline transverse cine sweep from submental region down to sternal notch
 - RIGHT LOBE:
 - Transverse cine sweep superior to inferior to include soft tissue just above and below the thyroid lobe (see below)
 - Sagittal cine sweep from lateral to medial, from internal jugular vein through mid-isthmus (see below)
 - Transverse still images
 - Begin with superior pole and obtain representative images through lobe
 - Longitudinal still images
 - Begin laterally, obtain representative images from lateral margin to medial margin
 - LEFT LOBE:
 - Repeat process

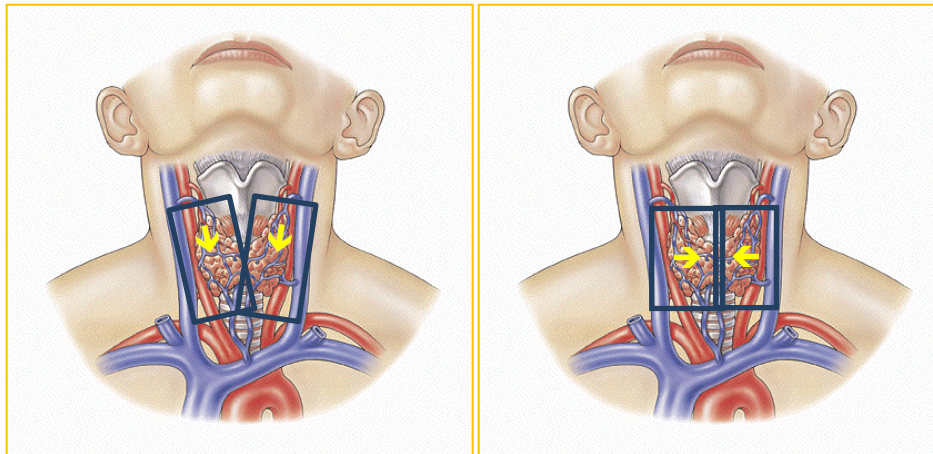
* - For solid/predominantly solid nodules ≥ 1 cm, include lymph node survey. See US Neck Node Survey protocol for details

- ISTMUS:
 - Transverse cine sweep
 - Transverse still images
- Color Doppler:
 - Transverse color Doppler image, midline at isthmus
 - Longitudinal color Doppler of thyroid parenchyma of each lobe

- Cine sweeps:

Transverse Cine

Sagittal Cine (Thyroid)



Superior border: At thyroid cartilage, above superior pole
 Inferior border: to clavicular head, below inferior pole
 Lateral border: Carotid/Jugular Complex
 Medial border: Mid Isthmus

- If thyroid nodules identified:
 - Up to EIGHT (8) index nodules will be specifically interrogated utilizing the process below:
 - Up to THREE (3) nodules per lobe, up to TWO (2) nodules in isthmus.
 - Number index nodules:
 - *Nodule R1, Nodule R2, Nodule R3; Nodule L1, Nodule L2, Nodule L3; Nodule I1, Nodule I2.*
 - An index nodule will be ≥ 1 cm in maximal diameter and mostly solid/entirely solid, or any nodule ≥ 1.5 cm. If more than 8 index nodules are present, obtain measurements for the most solid nodule, solid nodules with the most hypoechoic components, and nodules with microcalcifications and/or dystrophic or rim calcifications (i.e. Most suspicious nodules).
 - For each nodule, obtain measurements in 3 dimensions, dual screen side-by-side, without and with calipers on sequential images. Nodules should be measured as follows: in LONGITUDINAL PLANE, obtain longest cranio-caudal dimension. The, in AXIAL PLANE, obtain 2nd and 3rd dimension, transverse and anterior-posterior measurements.

* - For solid/predominantly solid nodules ≥ 1 cm, include lymph node survey. See US Neck Node Survey protocol for details

- For each nodule, obtain images without and with color, either dual screen side-by-side or on sequential images.
- Nodal Survey - See specific imaging protocol
 - Not routinely required.
 - Obtain if abnormal/suspicious lymph nodes incidentally noted at time of routine thyroid image acquisition,
 - or if solid/predominantly solid thyroid nodules ≥ 1 cm are identified (see appendix).
 - Obtain transverse cine sweeps of central neck (Levels 1 and 6, mandible to sternum) and lateral neck (Levels 2-4, submandibular gland to clavicle) at a minimum. **No need to obtain static images unless abnormal lymph nodes identified.**
 - **No need to measure normal lymph nodes.**
- Data page(s)
 - Use Imorgon diagram to annotate thyroid nodules and abnormal lymph nodes (if applicable), their sizes, and suspicious features (see Thyroid Nodule Imaging Cheat Sheet below for appropriate annotations).

PROCESSING:

- Review examination images and data
- Export all images to PACS
- Confirm data in Imorgon
- Document relevant history and any study limitations

REFERENCES:

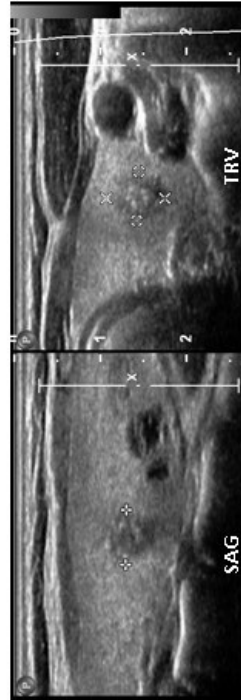
- ACR TI-RADS, available online: <https://www.acr.org/Clinical-Resources/Reporting-and-Data-Systems/TI-RADS>
- Tessler FN, Middleton WD, Grant EG et al. ACR Thyroid Imaging, Reporting, and Data System (TI-RADS): White Paper of the ACR TI-RADS Committee, JACR 2017, 14(5), pp 587-595
- ACR-AIUM Practice Guideline (Revised 2007)
- ATA Guidelines (Revised 2015)
- Som PM, et al. Imaging-Based Nodal Classification for Evaluation of Neck Metastatic Adenopathy, AJR 2000, 174

* - For solid/predominantly solid nodules ≥ 1 cm, include lymph node survey. See US Neck Node Survey protocol for details

APPENDIX:







Thyroid Nodule Imaging Cheat Sheet

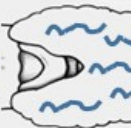
- Measure up to 3 nodules per lobe, up to 2 in isthmus.
 - o Number superior-to-inferior
 - o R1-R3; L1-L3; I1, I2
- Criteria for measuring (in descending order of importance):
 1. Any nodule w/ echogenic foci or calcs (without comet tail), then
 2. Any nodule > 1cm, predominately solid, then
 3. Any nodule \geq 1.5 cm solid or cystic
- Measure using **DUAL** screen
- Acquire images w/o and then w/ calipers
- First measurement in Long/Sag (cc dimension only)
- Then, at largest point, measure in Axial (Trv and AP dimensions)



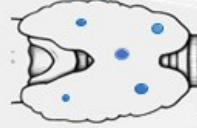
- If nodule is being measured, **INCLUDE NECK SWEEPS**
 - o Measure only **ABNORMAL** lymph nodes

Thyroid Key*

- Cystic 
- Solid 
- Cystic w/ solid area 
- Solid w/ cystic area 
- Complex 
- Calc 



- Heterogeneous Lobe



- Multiple small nodules/cysts

*Imorizon Worksheets

* - For solid/predominantly solid nodules \geq 1cm, include lymph node survey. See US Neck Node Survey protocol for details

ACR TI-RADS Reporting Lexicon

Nodule size

- Maximum diameter as seen on longitudinal, anteroposterior, or transverse measurements (see protocol for measurement guidelines)

Composition

- Solid – composed entirely of or nearly entirely of soft tissue – High sensitivity for malignancy
- Predominantly solid – soft tissue components $\geq 50\%$
- Predominantly cystic – cystic components $\geq 50\%$
- Spongiform – Composed predominantly ($>50\%$) of tiny cystic spaces
- Complete cystic

Echogenicity

- Anechoic
- Hyperechoic (relative to thyroid)
- Isoechoic (relative to thyroid)
- Hypoechoic (relative to thyroid)
- Very hypoechoic (relative to strap muscle) – High specificity for malignancy

Shape

- Taller-than -wide: ratio > 1 anteroposterior diameter to horizontal diameter (as measured in transverse plane)
- NOT Taller –than- wide

Margins

- Smooth – well-defined, uninterrupted, curvilinear edge
- Irregular – spiculated, jagged, or with sharp angles
- Lobulated – soft tissue protrusions, single or multiple
- Ill-defined – border difficult to distinguish from thyroid parenchyma

Echogenic Foci

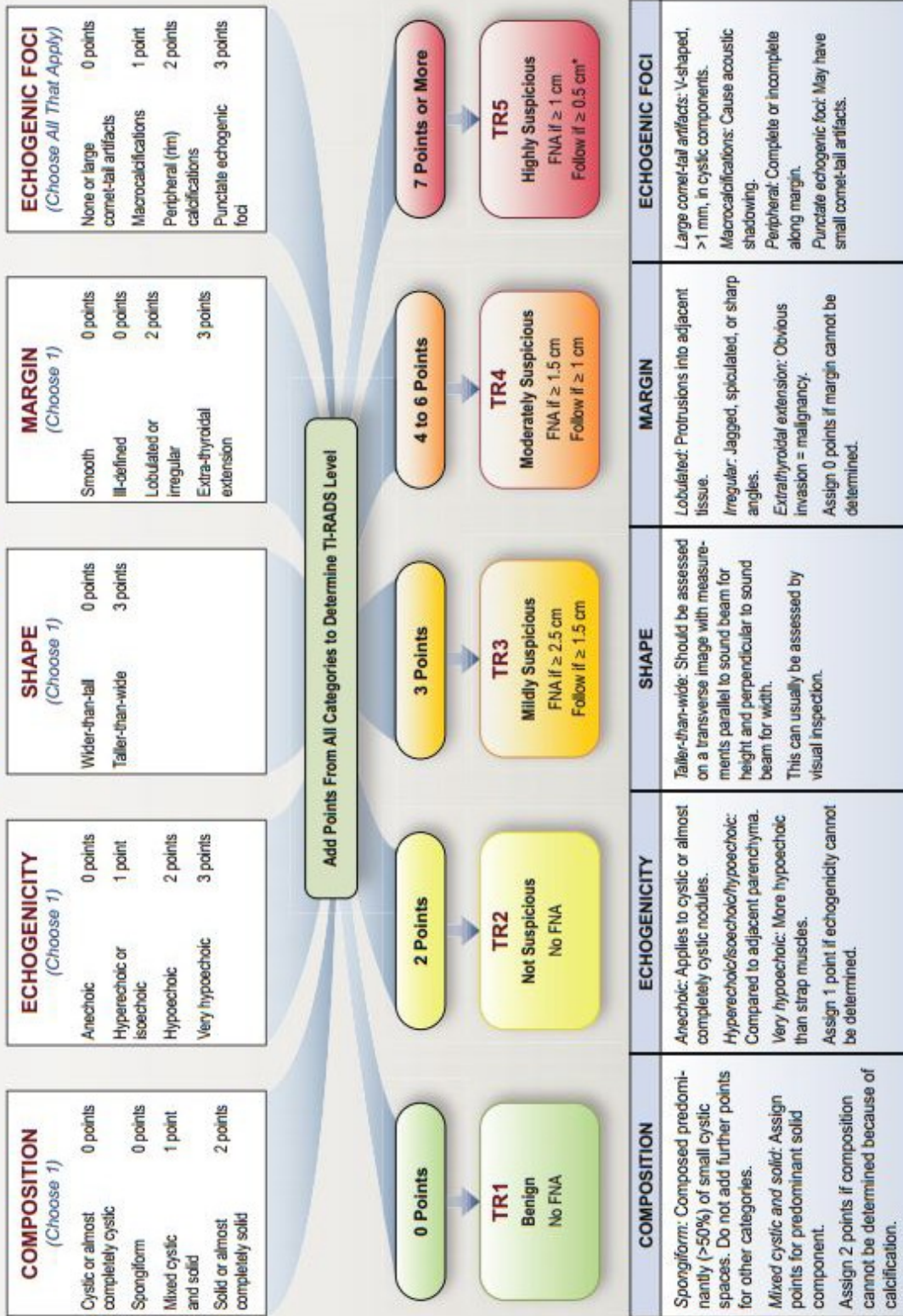
- Microcalcifications – punctate, $< 1\text{mm}$, without posterior comet tail artifact
- Macrocalcifications – large enough to produce posterior acoustic shadow
- Peripheral calcifications – rim or thin calcification along the margin
- Comet tail artifact – reverberation artifact $>1\text{-}3\text{ mm}$ long seen deep to echogenic focus, triangular in shape

Ancillary features

- Extrathyroidal extension
- Abnormal lymph nodes: $>1\text{cm}$ short axis, rounded or lobulated contour, loss of echogenic hilum, abnormal flow (outside of hilum), cystic components, internal echogenic foci, heterogeneity

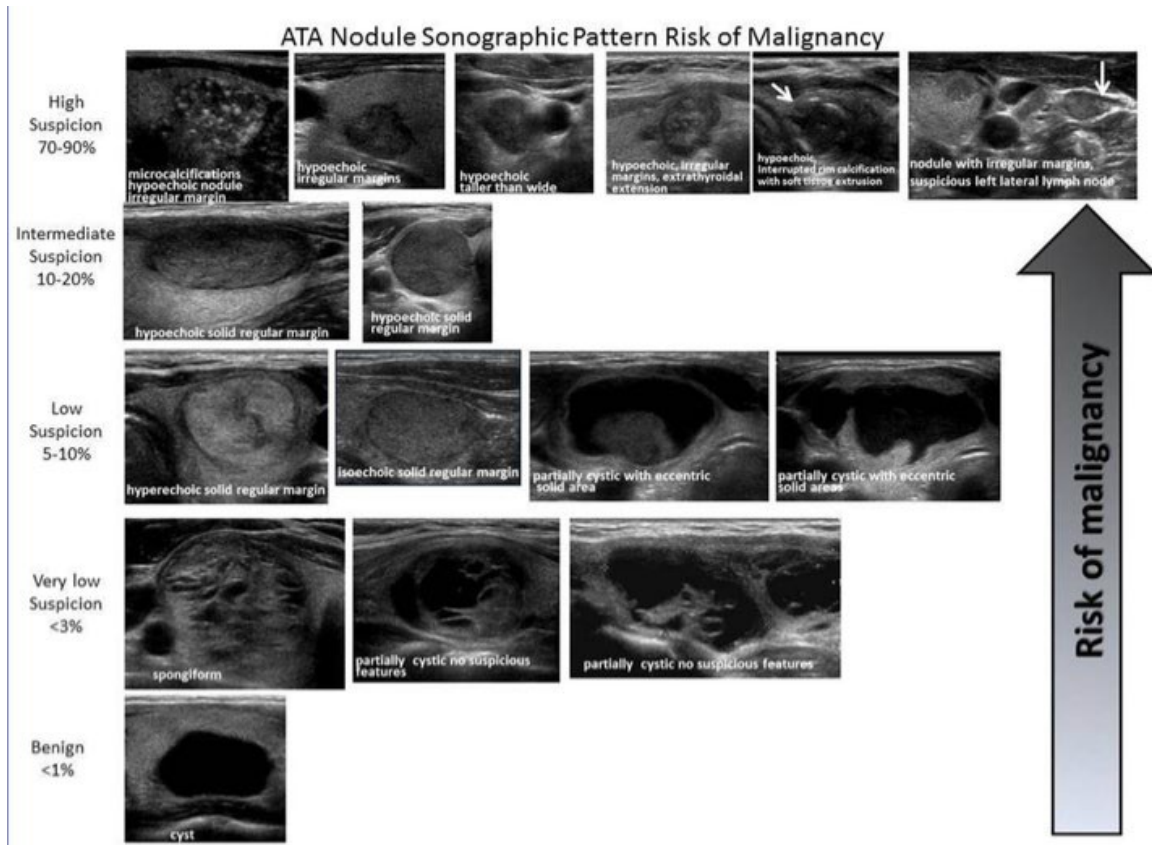
* - For solid/predominantly solid nodules $\geq 1\text{cm}$, include lymph node survey. See US Neck Node Survey protocol for details

ACR TI-RADS



*Refer to discussion of papillary microcarcinomas for 5-9 mm TR5 nodules.

* - For solid/predominantly solid nodules ≥ 1 cm, include lymph node survey. See US Neck Node Survey protocol for details



2015 American Thyroid Association (ATA) Management Guidelines for Adult Patients with Thyroid Nodules and Differentiated Thyroid Cancer.

REVISION HISTORY:

SUBMITTED BY:	David T. Fetzer, MD	Title	Medical Director
APPROVED BY:	David T. Fetzer, MD	Title	Medical Director
APPROVAL DATE:	01-31-2016		
REVIEW DATE(S):	09-24-2018		Lori Watumull, MDw
REVISION DATE(S):	08-07-2017	Brief Summary	Added information regarding neck lymph node imaging
REVISION DATE(S):	04-23-2018	Brief Summary	Added information about ordering/number thyroid nodules; updated requirements for lymph node survey
REVISION DATE(S):	09-12-2018	Brief Summary	Transition from 2015 ATA to ACR TI-RADS imaging and reporting guidelines
REVISION DATE(S):	09-24-2018	Brief Summary	Minor edits for clarification

* - For solid/predominantly solid nodules ≥ 1 cm, include lymph node survey. See US Neck Node Survey protocol for details