

UT Southwestern Department of Radiology

Ultrasound- Hips Dynamic Evaluation

PURPOSE:

To evaluate the hip joint for developmental dysplasia

AGE RANGE:

Less than or equal to 6 months. Exam must be scheduled **4 weeks AFTER 40-week gestational age to prevent a false positive diagnosis**. If child was born premature, they may be seen up until 6 months corrected age, but no sooner than 44 weeks gestational age.

SCOPE:

Applies to all ultrasound Hips Dynamic evaluation studies performed at Imaging Services / Radiology

INDICATIONS:

CPT Code : 76885

- Abnormal or equivocal findings on physical or imaging examination of the hip.
- Any family history of Developmental dysplasia of the hip (DDH).
- Breech presentation regardless of gender.
- Oligohydramnios and other intrauterine causes of postural molding
- Neuromuscular conditions
- Monitoring patients with DDH being treated with a Pavlik harness or other splint devices.
- Asymmetrical hip folds
- Hip clicks
- Age range less than 6 months unless premature.

CONTRAINDICATIONS:

No absolute contraindications

EQUIPMENT:

A real-time linear array transducer with a frequency range 22-2 MHz that provides adequate penetration of posterior joint.

PATIENT PREPARATION:

- The patient should lay supine
- The patient should be partly undressed from the hip down with the ability to remove and/or manipulate the diaper for the test.
- It may be helpful to feed the baby just prior to the exam.
- It is also possible to give the baby a pacifier or to bottle feed the infant during the exam.

UT Southwestern Department of Radiology

- Position parent to sit or stand where the infant can see and hear their voice to make him or her more relaxed.

EXAMINATION:

GENERAL GUIDELINES:

A complete examination includes evaluation of the head of the femur position, ilium, lower echogenic rim, acetabulum fibrocartilagenous tip of the Labrum, and the ischium.

EXAM INITIATION:

- Introduce yourself to the patient (AIDET)
- Verify patient identify using patient name and DOB
- Explain Test
- Obtain patient history
- Enter and store data page
- Place the patient supine and the transducer positioned over the lateral or posterior-lateral aspect of the hip.

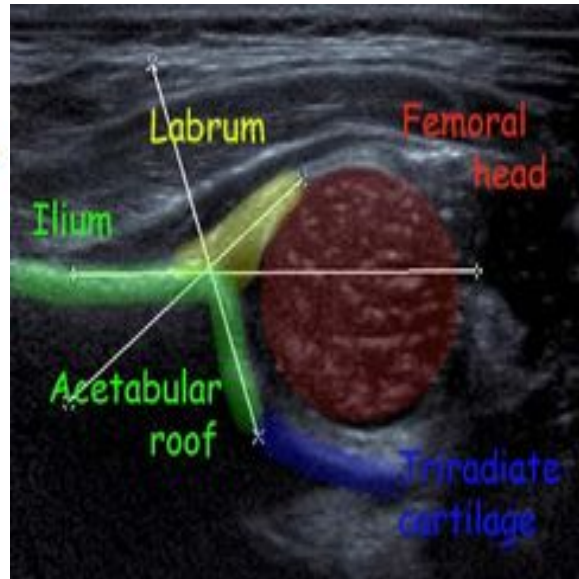
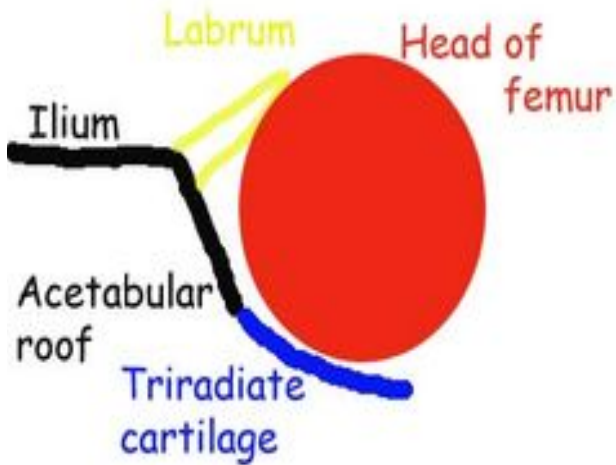
TECHNIQUE CONSIDERATIONS:

- Do not remove the Pavlik harness unless instructed by orthopedic doctor.
- Do not stress maneuvers in harness unless instructed by doctor.
- Patients should undergo ultrasound screening at 4-6 weeks following birth.
- The study becomes less reliable compared to radiography as ossification of the femoral head progresses.
- Ultrasound Hip Dynamic is not recommended for infants older than 6 months.
- The hip is examined in a neutral position at rest and in flexion.
- With the hip flexed the femur is stressed
- Images are obtained in transverse and coronal planes with respect to the body.

DOCUMENTATION:

- Right Coronal Images (Labeled- Long Right Hip Flex {stress})
 - Obtain 2 images in neutral
 - Obtain 2 images with stress
- Right Transverse images (Labeled-Trans Right Hip Flex {stress})
 - Obtain 2 images in neutral
 - Obtain 2 images with stress
- Left Coronal Images (Labeled- Long Left Hip Flex {stress})

- Obtain 2 images in neutral
- Obtain 2 images with stress
- Left Transverse images (Labeled- Trans Left Hip Flex {stress})
 - Obtain 2 images in neutral
 - Obtain 2 images with stress



PROCESSING:

- Review examination images and data
- Export all images to PACS
- Document relevant history and impressions in primordial.
- Present images to Radiologist

REFERENCES:

Siegel, Marilyn, (2002). Pediatric Sonography. Philadelphia, PA: Lippincott Williams and Wilkins.

<https://www.acr.org/-/media/ACR/Files/Practice-Parameters/US-Hip-Dys.pdf>

REVISION HISTORY:

SUBMITTED BY:	Samantha Lewis, B.S., RDMS	Title	Ultrasound Team Leader-Plano
APPROVED BY:	Jeannie Kwon, M.D.	Title	Director of Ultrasound
APPROVAL DATE:	08/28/2019		
REVIEW DATE(S):			

UT Southwestern Department of Radiology

REVISION DATE(S):	6/27/18 2/25/2019	Brief Summary	Added 2 images with alpha angle Removed alpha angle measurements
------------------------------	------------------------------	--------------------------	---