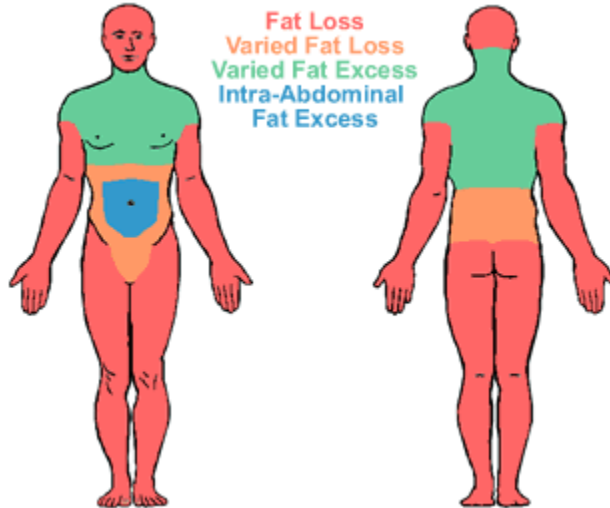


## Acquired: Lipodystrophy in HIV-infected Patients (LD-HIV)



This type of lipodystrophy seen in Human Immunodeficiency Virus (HIV)-infected patients has been associated with long duration of protease inhibitor drug therapy. Although protease inhibitors appear to be a strongest link to HIV lipodystrophy interactions among protease inhibitors and other antiretroviral drugs, and the HIV virus may also contribute to HIV lipodystrophy.

The precise mechanism by which lipodystrophy occurs in HIV infected is not known. Patients lose subcutaneous fat from the face and both arms and legs including the buttocks. These subjects develop increased muscularity in the arms and legs with prominent superficial veins. At the same time excess fat may accumulate in the neck and truncal region causing "double chin", "buffalo or camel hump" and increased abdominal girth commonly known as "crixivan belly". Both men and women complain of growth in breast size. The patients may also develop glucose intolerance but diabetes mellitus develops rarely. Many patients have high levels of serum cholesterol and triglycerides.

### References

- Misra A, Peethambaram A, Garg A. Autoimmune derangements in acquired partial lipodystrophy: report of 35 cases and review of the literature. *Medicine(Baltimore)* Jan;83(1):18-34. Review
- Haque WA, Shimomura I, Matsuzawa Y, Garg A. Serum adiponectin and leptin levels in patients with lipodystrophies. *J Clin Endocrinol Metab.* 2002 May; 87(5):2395
- Garg Lipodystrophies. *Am J Med.* 2000 Feb;108(2):143-52. Review.