

Anatomy: Rheumatology Pelvis
 Sub-Anatomy: Pelvis 1.5T or 3T

- Exams **ORDERABLE- Pelvis**
 - Routine Coil: Torso coil

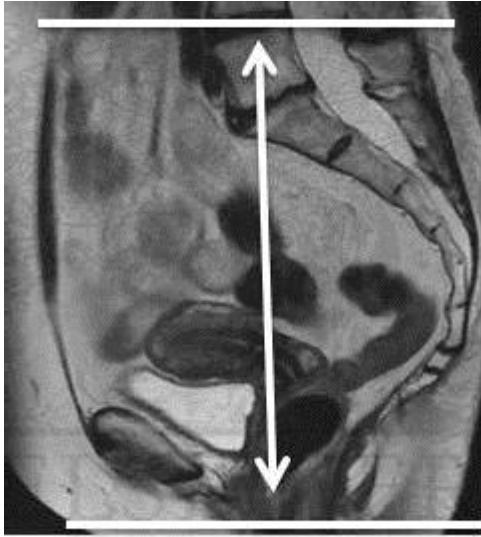
SEQUENCE - BASICS																
PLANE	SEQ	Slice thickness (mm)	Misc / Comment	M T X	% R F O V	Gap (mm)	Voxel size (mm)	TR	TE	F A/ TI	Nex Avg Acq	NS	ETL Turbo Factor	Phase Encode	Scan TIME (min)	Pixel Shift BW-kHz
ROUTINE																
	3 plane scout		Only GRE													
1	AX T2 FS	4x0.6x0.7				0.4		4000	50-65							
2	AX T1	4x0.6x0.7						600	6-9							
3	COR T1	5x0.6x0.7				0.5		600	6-9							
4	COR STIR	5x0.6x0.7				0.5		2000	25-35							
5	SAG T2 FS	5x0.6x0.7						4000	50-65							
6	AX DWI	5mm				0.5										
7	AX mDIXON PRE	3mm	3D			0										
8	COR 4D TRAK	1mm	25 dynamic scans													
9	AX mDIXON POST	3mm	3D			0										
↓ OPTIONAL ↓																
4	AX STIR	4x0.6x0.7	Failed fat sat			0.4		2000	25-35							

Instructions: FOV and Coverage- On axials and coronals, cover from L4-5 to just below lesser trochanters and from skin to skin.

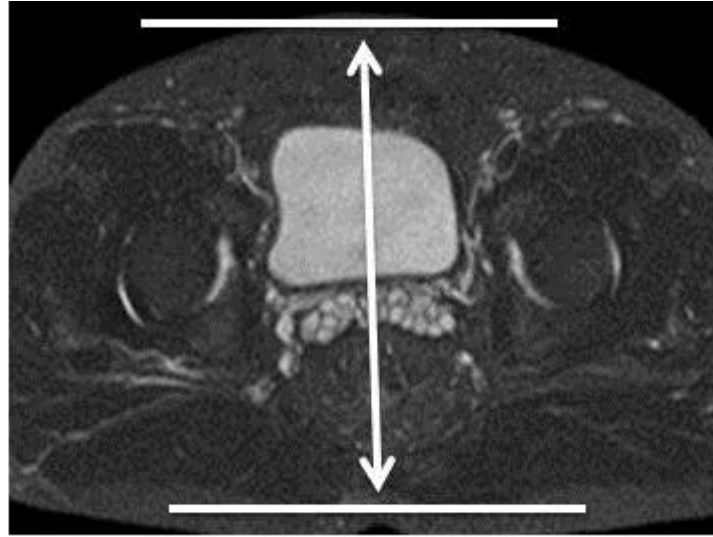
Others- Always put marker at the site of most pain, injury or swelling. If motion observed, stop the scan, instruct patient to lay still and repeat the sequence using MultiVane or BLADE

Others- Always put marker at the site of most pain, injury or swelling. If motion observed, stop the scan, instruct patient to lay still and repeat the sequence.

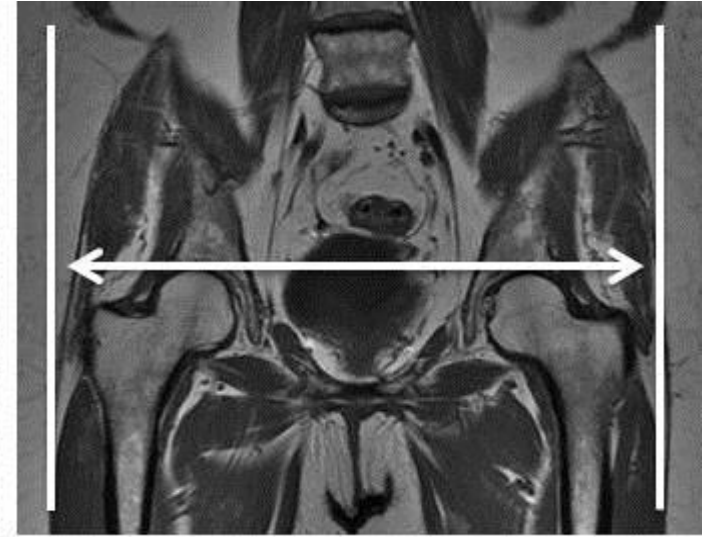
4D TRAKS – Inject contrast and scan at the same time. 2cc/sec 25 dynamic scans.



Axial Coverage



Coronal Coverage



Sagittal Coverage