

## UT Southwestern Department of Radiology

### US of hand/wrist- Orderable: US both extremities complete

Indication: assess for synovial hypertrophy, hyperemia/hypervascularity, bony erosion vs. spur formation; Rheumatology scan

Imaging protocol: all images obtained in **longitudinal** orientation **dorsal hand and wrist**, transverse images may be added as needed or if there is focal abnormality. Use both grey scale and color Doppler examination. Keep velocity scale lower for color Doppler and if no flow detected- try power Doppler as well.

#### WRIST:

1. Distal radioulnar joint- without and with Doppler
2. Radiocarpal joint - without and with Doppler
3. Radiocarpal joint at mid wrist - without and with Doppler
4. Ulnocarpal joint - without and with Doppler
5. Midcarpal sweep and take representative image - without and with Doppler

#### HAND:

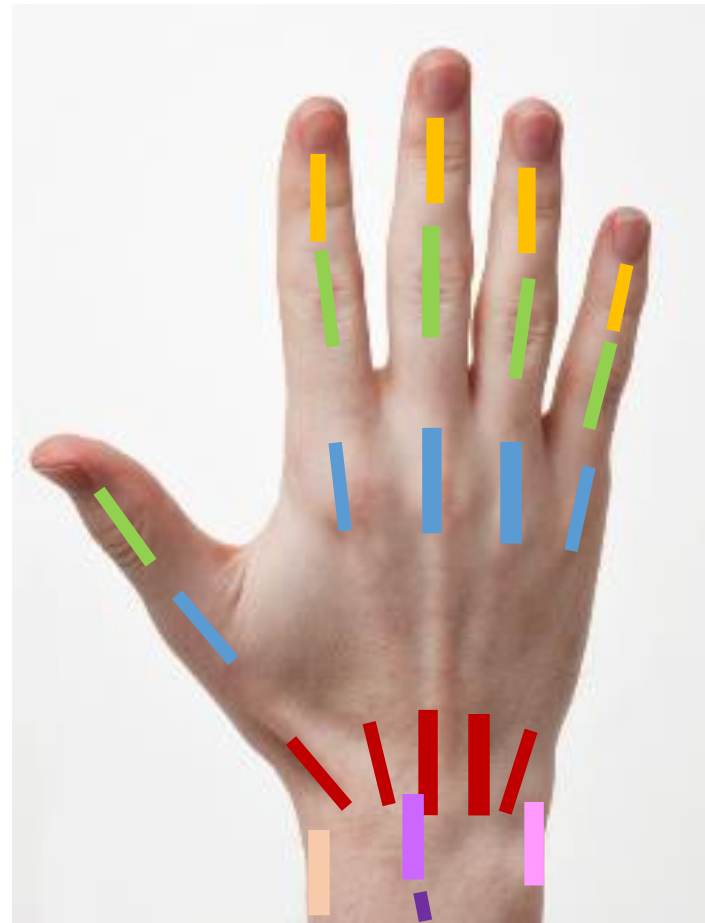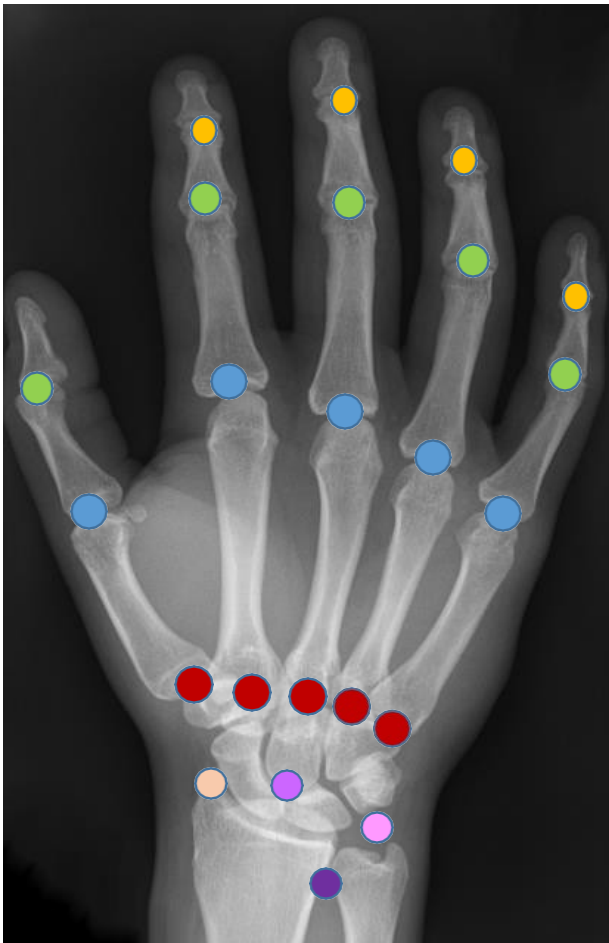
6. Thumb:
  - a. CMC (carpometacarpal joint) - without and with doppler
  - b. MCP (metacarpophalangeal joint) – without and with doppler
  - c. IP (interphalangeal joint) – without and with doppler
7. Index finger
  - a. CMC (carpometacarpal joint) - without and with doppler
  - b. MCP (metacarpophalangeal joint) – without and with doppler
  - c. PIP (proximal interphalangeal joint) – without and with doppler
  - d. DIP (distal interphalangeal joint) – without and with doppler
8. Long finger
  - a. CMC (carpometacarpal joint) - without and with doppler
  - b. MCP (metacarpophalangeal joint) – without and with doppler
  - c. PIP (proximal interphalangeal joint) – without and with doppler
  - d. DIP (distal interphalangeal joint) – without and with doppler
9. Ring finger
  - a. CMC (carpometacarpal joint) - without and with doppler
  - b. MCP (metacarpophalangeal joint) – without and with doppler
  - c. PIP (proximal interphalangeal joint) – without and with doppler
  - d. DIP (distal interphalangeal joint) – without and with doppler
10. Small finger
  - a. CMC (carpometacarpal joint) - without and with doppler
  - b. MCP (metacarpophalangeal joint) – without and with doppler
  - c. PIP (proximal interphalangeal joint) – without and with doppler

## UT Southwestern Department of Radiology

d. DIP (distal interphalangeal joint) – without and with Doppler

Tendons:

11. Extensor tendon sweep and take picture if abnormal, or if there is tenosynovitis (circumferential fluid), or ganglion (measure any focal swelling and put Doppler on it).
12. Flexor tendon sweep and take picture if abnormal, or if there is tenosynovitis (circumferential fluid), or ganglion (measure any focal swelling and put Doppler on it).
13. Take grey scale image and Doppler of any focal area of concern (pain, swelling, tenderness)



**WRIST:**

## UT Southwestern Department of Radiology

**DRUJ (Distal RU joint)**- without and with doppler

**RC (Radiocarpal joint)** - without and with doppler

**UC (Ulnocarpal joint)** - without and with doppler

**MC (Midcarpal joint)** - without and with Doppler

### **EACH DIGIT**

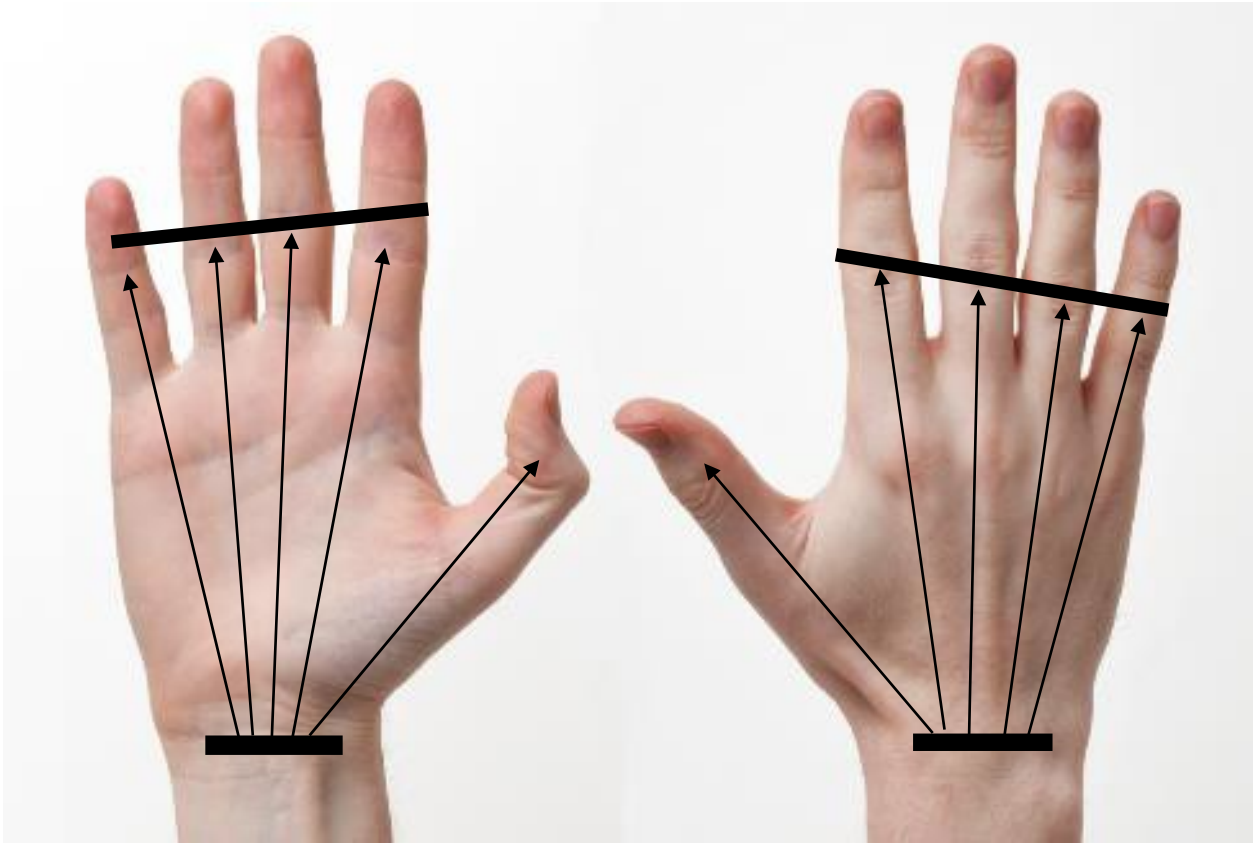
**CMC (carpometacarpal joint)** - without and with doppler

**MCP (metacarpophalangeal joint)** – without and with doppler

**IP (thumb) or PIP (proximal interphalangeal joint)** – without and with doppler

**DIP (distal interphalangeal joint)** – without and with doppler

TENDONS



Volar – flexor tendon sweep

Dorsal – extensor tendon sweep