

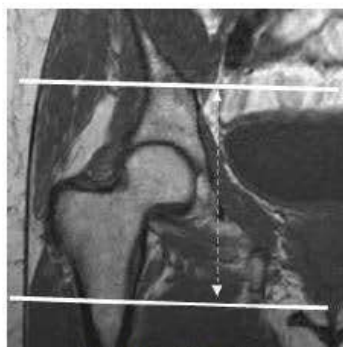
Anatomy: **Unilateral Hip**
 Sub-Anatomy: **HIP- 1.5T**

- Exams **ORDERABLE- HIP – Unilateral**
 - Routine Coil: **HIP (Torso coil)**

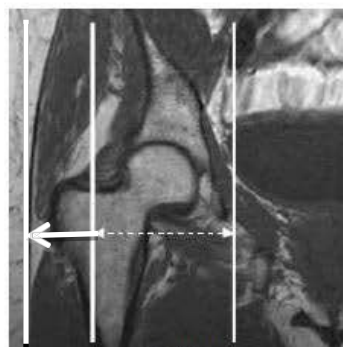
SEQUENCE - BASICS										
PLANE	SEQ	Slice thickness (mm)	Misc / Comment	gap	TR	TE	FA/TI		NS	ETL Turbo Factor
ROUTINE										
	3 plane scout		Only use GRE							
1	Cor PD	4x0.5x0.6		10%	4000	35-40				
2	Cor PD FS	4x0.5x0.6		10%	4000	35-40				
3	Sag PD FS	4x0.5x0.6		10%	4000	40-45				
4	Ax PD FS	4x0.5x0.6		10%	4000	35-40				
5	Oblique Ax PD	4x0.5x0.6		10%	4000	40-45				
6	Ax T2 Dixon (if possible) (or) Ax In/Out	5x0.5x0.6		10%	4000	55				
↓ OPTIONAL ↓										
	Cor STIR	4x0.5x0.6	Failed fat sat	10%	4000	30-35				

Instructions: FOV and Coverage- On axials, cover above the acetabulum to femoral metadiaphyseal junction. On coronals, just anterior to femoral vessels to behind the ischial spine/tuberosity. On sagittals, cover from medial to acetabulum to slightly lateral to greater trochanter.

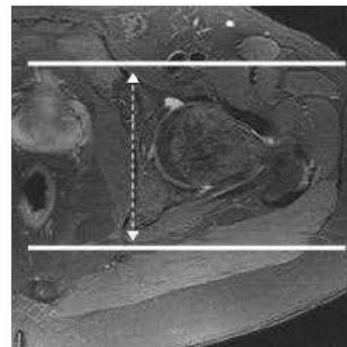
Others- Always put marker at the site of most pain, injury or swelling. If motion observed, stop the scan, instruct patient to lay still and repeat the sequence.



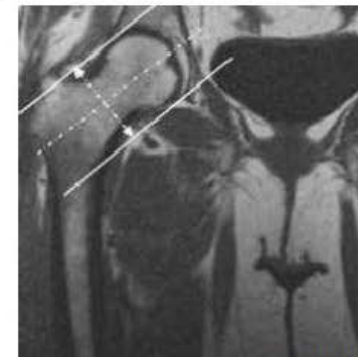
Axial Image Coverage



Sagittal



Coronal



Oblique Axial