

<b>Protocol</b>	<b>Study</b>
1	Routine brain
1G	Trauma or AVM brain - routine + axial gradient echo locator + FSE T2 axial
1U	Uncooperative patient brain
1MS	Non contrast MS brain – Routine + axial SD 256 x 512 thru brainstem and post. fossa
2	Routine Contrast Brain gad axial and coronal
2B	Brain + gad in all 3 planes
2G	#2 + axial gradient echo locator +FSE T2 axial
2P	#2 + axial perfusion
2SS	#2 + single voxel spectroscopy
2CS	#2 + CSI spectroscopy
2SSCS	#2 + single and multivoxel spectroscopy
2EF	M.S. brain post contrast

3	Routine Lumbar spine
3T2	Routine + FSE T2 axials (r/o spinal stenosis protocol)
3S	Routine + sagittal STIR
4	Routine L/S with contrast
4T2	Routine 4 + FSE T2 axials (post op back protocol)
4F	Routine 4 + add fat sat on post gads
4S	Routine 4 + sagittal STIR pre gad
5	Routine Cspine If on 3T add FIESTA axials thru area of suspected disc or cover C4 – T1
5S	Routine + sagittal STIR – Trauma C-spine protocol
5TL	Transverse ligament integrity protocol Fov 16 Center mid C2 to cover CVJ to C3 3mm T1 sag STIR sag 3mm T1 axial 0.7/1.4 mm FRFSE T2 axial or FIESTA axial if on 3T
6	Routine C/S + contrast in sag and axial planes
6EG	MS C-spine with contrast

includes a sag P. Density

- 6LP Lumbar plexus protocol  
#3 + T1 axial to cover  
from L1 – S1 instead of L3 - S1  
+ STIR axials from L1 – S1  
+ post gad axials to cover  
L1 – S1 + fat sat  
Film all axials so can see psoas muscles well.
- 7 Routine thoracic spine. Includes FSE T2 axials
- 7S Routine + sag STIR  
Trauma T/S
- 7C #7 + post gad sag & axial
- 7EG MS T/S with contrast – includes a sag P.D.
- 8 Screen spine to r/o cord compression if known malignancy. T1 sag  
entire spine.  
Dr. to check. If see cord compression can do FSE T2 axials only  
thru area.
- 8T Screen spine to r/o mets or acute trauma spine. T1 & STIR sag  
thru entire spine. FSE T2 axials thru any cord/canal compromise.
- 8G Screen spine to r/o epidural abscess. 8T + inject T1 sag post  
e/spine.  
T1 axial & FSE T2 axials thru any area of abscess.

- 12            Epilepsy protocol
- 12A           #12 + post gad 3D T1 VOL GE
- 12C           #12 + post gad T1 spin echo axial and coronal
- 13            Routine pituitary fossa pre and post contrast
- 13A           #13 + post gad axial thru pit fossa (radiation planning protocol)
- 13F           #13 + Flair coronal whole head
- 13AF          #13 + T1 axial & flair coronal post whole head (if 1<sup>st</sup> scan with no  
priors)
- 13D           #13 + dynamic pit fossa coronal  
(also use this for all r/o cushing's disease)
- 14            Routine non contrast pit fossa – no gad  
for pregnant or nursing mothers
- 16            Routine chiasm r/o mass  
3mm T1 sag                    ----16mm FOV  
3mm T1 coronal pit fossa ----16mm FOV  
FLAIR coronal head  
Inject - 3mm T1 sag & coronal post FOV 16  
   T1 5mm axial post gad whole head
- 17            Routine orbit  
T1 sag head  
3mm T1 coronal thru orbits FOV 16

4mm coronal STIR thru orbits FOV 16  
FLAIR axial whole head  
Inject - 3mm T1 coronal orbits + fat sat  
5mm T1 axial post gad whole head

17C           Cavernous sinus protocol  
Center 16 FOV on cavernous sinus  
3mm T1 coronal  
3mm T1 axial  
4mm FSE T2 coronal or  
Coronal T2 FIESTA if on 3T  
Inject- T1 ax  
T1 cor post + fat sat  
Flair axial whole head  
T1 sag post whole head

17CCF       Carotico-cavernous fistula protocol  
Same as cavernous sinus but add 27 centered on cavernous sinus  
pre-gad

18           Routine IAC with contrast  
To include DWI

18 screen   Thin T2 axial thru IAC's only  
1 IAC screening sequence only

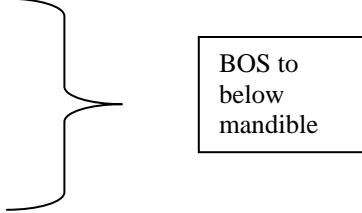
18F           Post op acoustic protocol. #18 + add fat sat to the T1 axial post  
gad thru IAC's and add FOV 16, 3mm T1 coronal post gad thru  
IAC's + fat sat instead of routine coronal post whole head.

18HS        Facial Hemispasm protocol

18 + FOV 16 thin FRFSE T2 axial centered on IAC's  
+ MRA (27) centered on IAC's  
If done on 3T replace FSE T2 axial with a T2 high res FIESTA  
axially thru IAC's

18PT Pulsatile Tinnitus protocol  
18 + 27  
Need to cover from above IAC down to C2 base.

19 Nasopharynx  
16 FOV. T1 sag  
T1 axial  
3mm T1 coronal  
FSE T2 axial  
STIR axial  
Inject – T1 ax post  
T1 cor post + fat sat



A vertical list of MRI sequences is shown on the left. A large right-facing curly bracket groups the sequences from 'T1 axial' down to 'STIR axial'. An arrow points from the center of this bracket to a rectangular box on the right containing the text 'BOS to below mandible'.

19S #19 but STIR must go BOS → clavicles

20R CSF leak study – Rhinorrhoea  
FOV 16  
3mm T1 coronal  
4mm FSE T2 coronal

Thin FRFSE T2 cisternogram sequence in the coronal projection  
If on 3T – Coronal FIESTA instead of FRFSE T2  
Need to cover from frontal bone to behind sphenoid sinus. Contrast depending on history.

- 20 O CSF leak study - Otorrhoea  
#20R but need to center on EAC/IAC to cover the temporal bone  
+ 16 FOV 4mm FSE T2 axial. Contrast depending on history.
- 20RC CSF leak with contrast #20R  
Inject – T1 cor post + fat sat, T1 ax post.
- 20 OC #20 O with contrast  
Inject – T1 axial post + fat sat  
T1 coronal post + fat sat
- 21 Routine parotids  
16 FOV  
T1 axial thru parotids (BOS → below parotids)  
FSE T2 axial (BOS → below parotids)  
STIR axial (BOS → below parotids)  
3mm T1 coronal thru parotids from IAC down  
Inject – T1 axial post  
T1 cor post + fat sat
- 21SM Routine submandibular (submaxillary) glands  
#21 but center on submandibular glands
- 22 Routine neck mass

16 to 18 FOV

Center on mass. If small - place skin marker on lesion.

T1 axial

T1 cor or sag depending on location of mass. If L or R → coronal

If anterior or post →

sag

T2 FSE axial

5mm STIR axial

Inject: T1 axial post + fat sat

T1 sag or coronal post + fat sat

23

Carotid body tumor protocol

#22 centered at carotid bifurcation in the neck.

+ 27 centered at bifurcation

24

Glomus Jugulare

16 FOV Center CVJ – jug fossa

T1 axial

4mm FSE T2 axial

STIR axial

3mm T1 coronal

FLAIR axial whole head

Inject – T1 axial

T1 coronal + fat sat

24ME

Middle ear mass

#24 but center all scans to the middle ear ie IAC/EAC and replace

FSE T2 axial

with a thin FRFSE T2 coronal or FIESTA coronal if on 3T.

- 24 frontal or Sinus mass, center on sinus of interest
- 24 ethmoid or FOV 16
- 24 sphenoid or T1 sag
- 24 maxillaryantum T1 axial
- 3mm T1 coronal
- 4mm FSE T2 Coronal
- STIR axial
- Inject: T1 axial
- T1 coronal + fat sat
- T1 Sag post whole head
- 
- 25 Trigeminal Neuralgia
- Do on 3T scanner
- FOV 16 center on cisternal trigeminal nerves
- T1 axial
- 3mm T1 coronal
- 4mm FSE Tx axial
- FIESTA axial T2 + Recon coronal & sag of nerves.
- Inject – T1 ax
- T1 cor + fat sat
- #27 – centered on nerves pregad.
- 
- 25V3 V3 protocol for perineural spread of disease
- FOV 16 - center BOS to mandible to include cavernous sinuses and Meckle's caves.
- T1 3mm coronal centered on Foramen ovale

T1 ax 3mm

4mm FSE T2 coronal

STIR axial

Inject – T1 ax

T1 cor post + fat sat

Need to be able to see cavernous sinuses and Meckle's caves well  
on all scans.

- 25V2      V2 protocol same as V3 but center on foramen rotundum
- 27            3D TOF COW & VBS angio
- 28            3D PC COW & VBS angio
- 31            3D TOF 6 slab MRA thru the neck
- 32            3D PC paracoronar venogram for sag sinus thrombosis
- 33            2D PC paracoronar venogram for sagittal sinus thrombosis
- 34            Bolus infused contrast coronal MR venogram for SS thrombosis –  
add this to all SS protocols – Then T1 axial & coronal post gad  
whole head.
- 35            Dementia protocol  
Sag T1 5mm midline  
Axial FLAIR 5mm  
T1 5mm coronal  
FSE T2 axial 5mm

DBS (deep brain stimulator) or STN protocol

There are two possibilities for this:

36 Pre- pre-op DBS MRI

36 Post- post DBS placement after the OR

37 Chiari CSF flow study.

Center CVJ

3mm T1 sag

1.5mm FRFSE T2 sag

CSF flow venc 5cc/sec in sag midline position.