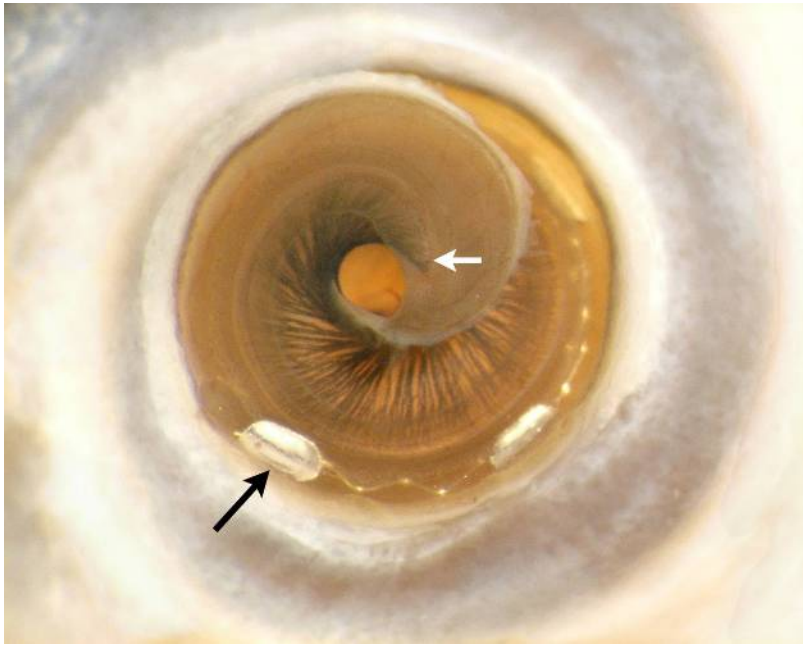


Apical cochlear turn showing a Med-El electrode array inserted to near the apical tip of the basilar membrane (white arrow). The black arrow indicates the apical-most electrode contact which is situated beneath the semi-transparent basilar membrane.

---



From Wright CG, Roland PS. Temporal bone microdissection for anatomic study of cochlear implant electrodes. *Cochlear Implants International* 2005;6(4):159-168. Copyright John Wiley & Sons Limited. Reproduced with permission.